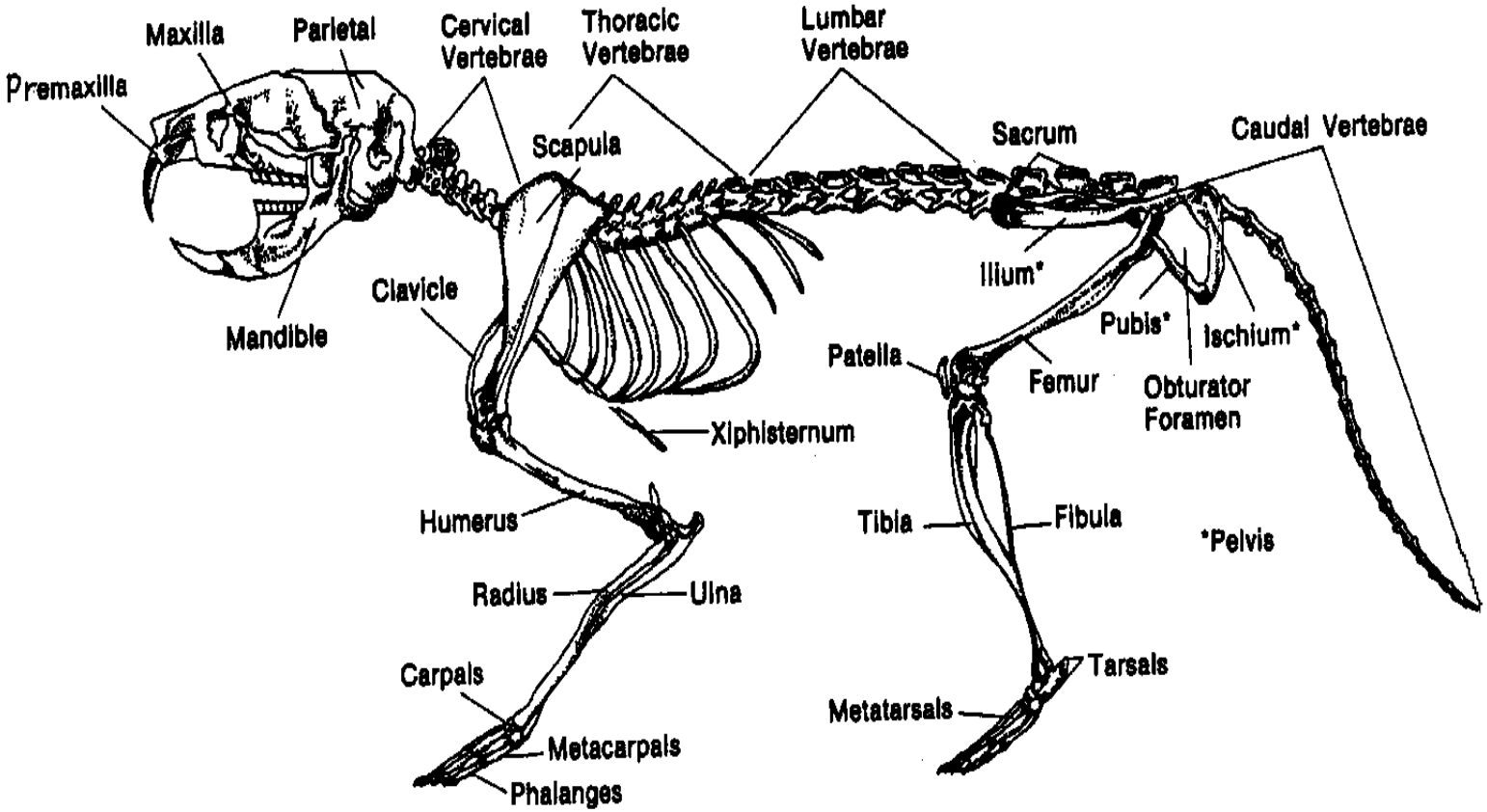
Premaxilla
Maxilla
Parietal
Cervical Vertebrae
Thoracic Vertebrae
Lumbar Vertebrae
Sacrum
Caudal Vertebrae
Scapula
Mandible
Clavicle
Ilium*
Pubis*
Ischium*
Patella
Femur
Obturator Foramen
Xiphisternum
Humerus
Tibia
Fibula
*Pelvis
Radius
Ulna
Carpals
Tarsals
Metatarsals
Metacarpals
Phalanges